

ORIGINAL ARTICLE

## Myringoplasties. A Retrospective Analysis of Our Surgical Outcomes<sup>☆</sup>

Ramón Balaguer García<sup>a,\*</sup>, María M. Morales Suárez-Varela<sup>b</sup>, José M. Tamarit Conejeros<sup>a</sup>, Gabriela Agostini Porras<sup>a</sup>, Virginia Murcia Puchades<sup>a</sup>, José Dalmau Galofre<sup>a</sup>

<sup>a</sup> Servicio de Otorrinolaringología, Hospital Universitario Dr. Peset, Valencia, Spain

<sup>b</sup> Área de Medicina Preventiva y Salud Pública, Universidad de Valencia, Spain

Received 7 September 2010; accepted 7 December 2010

### KEYWORDS

Myringoplasty;  
Ear cartilage;  
Anatomical success;  
Functional success

### Abstract

**Objective:** The aim of this study was to present myringoplasty case results in our department. Different factors were studied to confirm their prognostic value.

**Materials and methods:** A total of 126 myringoplasties from 2006 until 2010 were reviewed, collecting patient-related details, descriptions of the anatomical defect and the most interesting surgical aspects.

**Results:** Subtotal perforations (35.7%) were the most frequently observed. In 89.7% of the operations, the transcanal approach was preferred. The medial technique (underlay) to the tympanic membrane was the most performed (97.6%). Cartilage was the principal graft used (82.5%).

Complete closure of the perforation was obtained in 71.1% of the cases at 6 months follow-up. Recurrences of the perforations were of minimal size in 11.9% of the cases, partial in 11.1% and with a cartilage fragment gap in 4.8%. The mean time in which these defects were registered was 3.82 months.

The mean post-operative auditory gain was 12.8 decibels at 6 months.

**Conclusions:** Myringoplasty is an appropriate technique for restoring tympanic integrity and obtaining functional benefit.

Dried middle ear mucosa and posterior perforations seem to be related with better functional results.

© 2010 Elsevier España, S.L. All rights reserved.

### PALABRAS CLAVE

Miringoplastia;  
Cartílago auricular;  
Resultados  
anatómicos;

### Miringoplastias. Un análisis retrospectivo de nuestros resultados

#### Resumen

**Objetivo:** El objetivo de este trabajo es presentar, de forma detallada, nuestros resultados en la cirugía de la reconstrucción de la membrana timpánica y sobre todo los diferentes factores que influyen en los resultados con el fin de contrastar su valor pronóstico.

<sup>☆</sup> Please cite this article as: Balaguer García R, et al. Miringoplastias. Un análisis retrospectivo de nuestros resultados. Acta Otorrinolaringol Esp. 2011;62:213–9.

\* Corresponding author.

E-mail address: balaguergarcia@gmail.com (R. Balaguer García).

## Resultados funcionales

**Métodos:** Hemos revisado un total de 126 miringoplastias desde 2006 hasta 2010, recopilando los datos del paciente, la descripción del defecto anatómico y los aspectos más relevantes de la propia intervención.

**Resultados:** Las perforaciones subtotaletas (35,7%) fueron las más frecuentes. En el 89,7% se realizó el abordaje transcanal. La técnica medial (*underlay*) fue la más empleada (97,6%). Como injerto se utilizó principalmente el cartilago (82,5%).

Se consiguió un cierre completo de la perforación en el 71,1% a los 6 meses de seguimiento. Las reperfectoraciones fueron de tipo puntiforme en el 11,9%, parcial en el 11,1% y dehiscencia de los fragmentos de cartilago en el 4,8%. El tiempo medio en el cual se registró el defecto de la cirugía fue a los 3,82 meses.

La ganancia auditiva media fue de 12,8 dB a los 6 meses de la intervención.

**Conclusiones:** La miringoplastia constituye una técnica adecuada para la restitución de la integridad timpánica y para la obtención de un beneficio funcional.

Un estado de la caja seco y las perforaciones posteriores parecen relacionarse con un mejor pronóstico funcional.

© 2010 Elsevier España, S.L. Todos los derechos reservados.

## Introduction

The aim of this work is to present case studies in our use of myringoplasty, focusing on cartilage as a graft to restore the integrity of the membrane. Among the various techniques for using cartilage, one of the most widespread is the so-called "lattice" technique described by Heerman.<sup>1</sup> We prefer to refer to cartilage myringoplasty without any other qualifications, given that the closure of the defect is not always performed in a "classic" manner with parallel fragments as in the lattice.

The advantages of this material over others are numerous. Among them are greater stability and rigidity without compromising the postoperative audiometric results, greater resistance to infection,<sup>2</sup> greater tolerance for prolonged periods of malnutrition,<sup>2,3</sup> the non-appearance of scarring retractions<sup>2,4</sup> and zero cost (as it can be obtained in the same surgical field).<sup>2</sup>

Myringoplasty is an established operation that achieves anatomical restitution in most patients undergoing this surgery. On the other hand, it is also a technique subject to great variability regarding results and follow-up times, which makes it difficult to compare between different studies. In any case, there are some variations of the technique that are currently considered, in general terms, the most appropriate.

Reconstruction of the tympanic membrane is also a challenge for the otolaryngologist. The factors involved in the proper ventilation of the space will influence to a greater or lesser extent the success or failure of the surgery.

We performed a detailed study of some of the variables involved in the technique of myringoplasty. We also conducted a statistical analysis to compare with other studies the value of these variables as predictors of the outcome of the intervention.

## Material and Methods

We conducted a retrospective study including the primary and secondary myringoplasties performed at the Hospital

Universitario Dr. Peset in Valencia from January 2006 to April 2010.

We collected cases of reoperation from our service as well as from other centres, selecting the results comparable to stages of primary techniques. However, we did not include very limited partial surgeries intended to correct pinpoint defects, since this could have masked the results of the first surgery. We also ruled out tympanoplasties whose purpose was to correct retraction pockets, mastoidectomies and ears with cholesteatoma, as well as all ossicular reconstruction techniques.

Following these exclusion criteria, we selected a total of 126 myringoplasties. Of these, we collected data regarding patient age, reason for perforation and description of the anatomical defect, including its location, extent and its relationship with respect to the tympanic frame.

Focusing on this last point, we provide a description of the items in each of these categories. The location of the perforation was defined as anterior, posterior, inferior, subtotal (3 quarters) and complete (lack of tympanum).<sup>5</sup> The extent of the perforation was considered as above or below 50% of the tympanic surface. Depending on whether perforations affected the tympanic ring or not, they were classified as marginal or central.

We used a surgery data collection protocol that included the approach route, the type of graft and the technique employed. We also described the mucosa of the pavilion or the presence of otorrhea, the condition of the chain and the anatomical integrity of the chorda tympani nerve. We did not include in the history any possible symptoms that might have arisen from its section (decreased salivary secretion and dysgeusia).

Revisions were carried out in the second week, first month, 2 months, 4 months and 6 months after surgery.

The ear packing was removed after the second week, while maintaining topical treatment with ciprofloxacin every 12 h continuously for 4 weeks.

We studied the anatomical and functional results of surgery. Anatomical outcome was defined as the condition of the tympanic membrane in postoperative controls: complete closure of the perforation or recurrence (punctiform,

dehiscence or partial), as well as the review interval in which the defect was noted for the first time. Persistence of the initial perforation was also included in the group of perforation recurrences.

Regarding functional outcomes, we collected the mean differential auditory threshold (DAT) at frequencies 500, 1000, and 2000 Hz (MAT)<sup>6</sup> before and after the intervention. We also recorded the hearing gain, which is the difference between the preoperative and postoperative MAT expressed as a percentage. Measurement of postoperative hearing was carried out after a minimum of 6 months after surgery. For this calculation, we did not include those patients who had a preoperative MAT equal to 0.

For both the analytical and descriptive statistical analyses, which related audiometric gain with any of the parameters studied, we discarded the patients in whom we carried out chain reconstruction with cartilage (6 cases). Neither did we include in this calculation the patients who had no hearing loss prior to surgery (8 cases). Data collection was performed through a questionnaire designed by a comprehensive review of the medical literature. This was applied to each medical history reviewed, preserving confidentiality. The database was exported to the SPSS v17 program for statistical analysis. The statistical tests applied were the chi-square and Student *t* tests for qualitative variables, as well as the ANOVA test for quantitative variables. We considered a value of  $P < .05$  as statistically significant.

## Results

Of the total 126 patients, 90.5% were cases of primary myringoplasty and 9.5% were secondary. The mean age of patients undergoing surgery was 37.75 years, with a standard deviation of  $\pm 16.12$  and a range of 5–74 years. Of these, 12.69% were under 18 years.

There was homogeneity in gender; 44.44% were male and 55.55% were female. In 56.3% cases, the operated ear was the left and in 44%, the right, and this difference was statistically significant (.043). Perforation as a sequel of otorrhea was the main cause in 97.3%, and only in 6.3% was it tympanic trauma.

Subtotal perforations (35.7%) were the type most frequently observed, followed by inferior (23%), anterior (19%), posterior (15.1%), complete (4.0%) and double (3.2%). Continuing with the descriptive analysis of perforation characteristics, in 40.47% of patients, the perforations were of a size greater than 50% of the tympanic surface and in 59.53% they were smaller. Practically all of the perforations were central. Only 2 cases of marginal perforation were recorded.

Focusing on the intervention itself (Table 1), it was noted that local anaesthesia was used in 78.6% of cases and general anaesthesia in 21.4%. The latter include cases of retroauricular approach or patients in whom less collaboration was expected, mainly due to the young age of the patient. For this type of surgery, we prefer to use the intrameatal or transcanal route whenever possible, and this is reflected in the statistics: this approach was used in 89.7% of cases and the retroauricular in 10.3%.

The medial (underlay) technique to the tympanic remnant was the most commonly used (97.6%). We also describe other, less common procedures, such as the use of a fat graft

**Table 1** Surgical Technique.

	Frequency	Percentage
<i>Anaesthesia</i>		
General	27	21.4
Local	99	78.6
<i>Approach</i>		
Retroauricular	13	10.3
Transcanal	113	89.7
<i>Type of graft</i>		
Cartilage	104	82.5
Perichondrium	16	12.7
Fat	2	1.6
Cartilage with skin	4	3.2
<i>Technique</i>		
“Hourglass”	2	1.6
Overlay	1	0.8
Underlay	123	97.6
<i>Mucosa</i>		
Normal	117	92.9
Pathological	9	7.1
<i>Otorrhea</i>		
Mucosa	4	3.2
Purulent	2	1.6
Dry	120	95.2

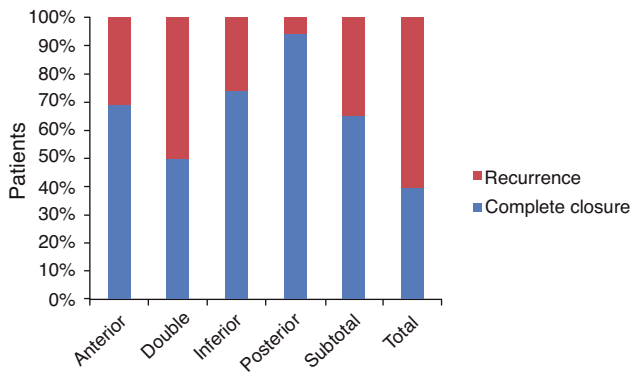
positioned as an “hourglass” with respect to the perforation in 2 patients and the lateral (overlay) technique, described in one case.

Cartilage was the most commonly used graft material, in 82.5% of cases. It must be mentioned that the use of this material was through the classic “lattice” technique,<sup>1</sup> and also through the use of a single or several fragments, moulded into the necessary shapes to achieve a seamless surface. In addition to cartilage, we also used tragal perichondrium in 12.7% of cases, mixed grafts with cartilage and skin in 3.2%, and other less conventional ones such as ear-lobe fat in 2 cases. The predominant source of cartilage was the tragus (96.46%). Cartilage from the cymba was employed in 3 patients and from the auricular shell in one case.

We also attach great importance to the characteristics of the mucosa of the pavilion. Faced with a mucosa that is shiny, turgid, with granulomas, etc., we think that surgery should be postponed to attempt to improve this situation before the intervention, and this is reflected in the data. The pavilion was dry in 95.2% of patients. Similarly, the mucosa showed no signs of inflammation in 92.9% of cases.

Following with the intratympanic findings, the chorda tympani nerve was not evidenced in 58.73% of cases and was evidenced and anatomically intact in 40.47%. Unfortunately, it was sectioned in one patient. With regard to the ossicular chain, it should be mentioned that in 19.84%, the malleus handle was too verticalized to position the cartilage fragments properly, so it had to be amputated. There have also been documented cases of erosion of the handle in 4.76% and of the incus in 8.73% of patients.

As for the endomeatal cure at the end of surgery, a racket-shaped silastic sheet was used on the neotympanic



**Figure 1** Results according to anatomical location of the perforation.

membrane in 4 patients. Subsequently, the tube was plugged with absorbent gelatine sponge and a self-expansive plug soaked in antibiotic solution in all patients.

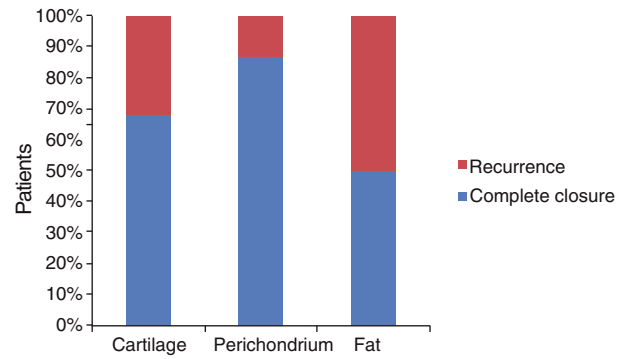
We obtained a complete closure of the perforation in 71.1% at 6 months follow-up. Recurrences of perforations were punctiform in 11.9%, partial in 11.1% and with dehiscence of the cartilage fragments in 4.8%. The median interval in which recurrences were collected was between the first and second month after the intervention. The mean  $\pm$  standard deviation of the month in which the surgery defect was registered was  $3.82 \pm 3.63$  months.

Anatomical results regarding the location of the perforation are shown in Fig. 1. From that information, we conclude that recurrences occurred more frequently in perforations of larger sizes (subtotals and totals) and in those in which tympanic margins were viewed with more difficulty, such as those with anterior location. Out of 4 cases of double perforation, complete closure was achieved in 2. We did not find any cases of dehiscence after the second month. Those of punctiform-type (8 cases) were the most common when the initial perforation was subtotal, followed by the partial (6 cases). Among those of anterior location, recurrences were distributed evenly (2 dehiscence, 2 partial and 2 punctiform). In the inferior, there were 3 partial cases and 3 punctiform cases.

Anatomical results in terms of the graft used were the following: cartilage (combined or not with other materials), perichondrium and fat are shown in Fig. 2. This shows that recurrences were more frequent with the use of cartilage than with perichondrium. Fig. 3 shows the different types of recurrence and the time interval in which the defect was documented only in cases in which cartilage was used. This graph shows that dehiscence was registered between the first and second month after the operation and that partial and punctate recurrences were homogeneously distributed both in the counts of patients and in their distribution depending on the time interval.

With respect to the audiometric records, the mean and standard deviation of the preoperative MAT were  $24.1 \pm 8.31$  dB and that of the postoperative collected at least 6 months after surgery were  $11.09 \pm 8.74$  dB.

The mean hearing gain was  $12.8 \pm 6.3$  dB. Tables 2 and 3 show the mean hearing gain and standard deviation depending on the location of the perforation and type of graft used, respectively. As noted, we obtained a higher mean hearing



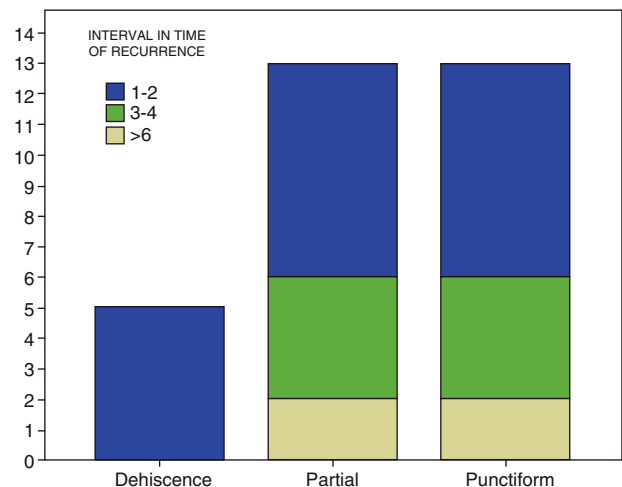
**Figure 2** Anatomical results by type of graft.

gain in posterior perforations, followed by the inferior and subtotal. The hearing benefit was also greater when perichondrium was used versus cartilage.

### Discussion

Myringoplasty is a consolidated technique that meets its primary objective, which is the closure of a perforation. The anatomical success of this surgery, in addition to the versatility of the technique, has led to the publication of numerous works using different methodologies and results. However, most authors offer complete closure figures around 85%.<sup>5,7-11</sup>

We obtained complete closure in 71.1% at 6 months after surgery, which is a lower figure than in our previous study,<sup>12</sup> with only 14% of recurrence. These worse outcomes are explained by two reasons: firstly, this review broadened the indications of cartilage as a graft, including more technically complex perforations with a consequently higher failure rate, and secondly, we had a larger sample size (126 versus 71). With a larger sample, the results are closer to the real success of the intervention, always depending on the methodology followed.



**Figure 3** Total count of patients in whom cartilage was used (Y axis), depending on the type of recurrence (X axis) and the intra-group distribution of the interval in months in which the defect occurred.



**Table 2** Mean Hearing Gain and Standard Deviation According to Location of Perforation.

Location	Mean Gain, dB	Standard Deviation, dB
Anterior	9.6	8.9
Double	4.2	4.4
Inferior	13.5	8.6
Posterior	17.4	7.5
Subtotal	13.5	8.1
Total	12.8	6.3

After myringoplasty, it is also possible to obtain a tonal hearing improvement of the patient. To carry out an analysis of the functional benefit of this surgery, we used the hearing gain, as described in the Materials and Methods section, after at least 6 months from the intervention; the reason was that it has been observed that hearing improvement takes place a few months after the intervention.<sup>13</sup>

We obtained a mean hearing gain of 12.8 dB. The figures in other reviewed articles were between 7.5 and 9.5 dB.<sup>8,13-15</sup>

Our most recent previous study had obtained a postoperative DAT under 30 dB (considered as social hearing, which allows a good adaptation to everyday life)<sup>12</sup> in 84.5% of the interventions. In this study, we obtained a DAT lower than 30 dB in 94.11% of patients.

This study aimed to evaluate the hearing gain regardless of anatomical closure of the perforation. It seems logical to think that the audiometric benefit would have been higher if we had excluded patients who had not achieved complete closure of the perforation.

With respect to the possible prognostic factors, based on the location of the perforation, some authors describe anterior perforations as the more complex to resolve.<sup>16,17</sup> Applebaum and Deutsch<sup>18</sup> published studies performed with fluorescein, showing that the anterior part of the tympanic membrane is less vascularized than the rest, justifying a higher failure rate when the perforation takes place at this level. Others feel that there is a higher rate of recurrence when the location is posterior<sup>19</sup> and several authors do not even find that the location of the perforation has a determining influence on the final results.<sup>20,21</sup>

According to available data, we found no statistically significant differences ( $P=.285$ ) in relation to clinical outcome depending on the location of the perforation. In contrast, we found a higher mean hearing gain in patients who presented a posterior perforation, with these differences being statistically significant ( $P=.048$ ).

**Table 3** Mean Hearing Gain and Standard Deviation According to Type of Graft Used.

Type of Graft	Mean Gain, dB	Standard Deviation, dB
Cartilage	12.5	8.5
Perichondrium	17.9	5.4
Fat	0.8	1.2
Total	12.9	8.4

The extent of perforation and its marginalization are probably 2 factors that adversely affect the prognosis of myringoplasties.<sup>8</sup> We did not find these differences to be statistically significant ( $P=.155$  and  $P=.918$ ).

A prior history of myringoplasty does not favour success.<sup>22,23</sup> It is in those cases when the cartilage appears to stand out as the material of choice.<sup>24,25</sup> In our study, we found no statistically significant differences between the type of intervention (primary or secondary) and the postoperative results, whether anatomical or audiometric ( $P=.205$  and  $P=.293$ ). Our low sample size of second interventions (11 cases) may explain the lack of significance, since anatomical success was significantly higher in cases of primary surgery (72% of complete closures) versus cases of secondary interventions (54% of complete closures).

As to the intervention itself, the underlay technique was the most widely used technique in our series. The type of approach would depend on the location of the perforation and the age of the patient, so it should not be considered as an isolated predictive factor.<sup>15</sup> Albera et al.<sup>26</sup> claim that the retroauricular approach is the most decisive prognostic factor in the outcome of surgery, owing to a better visualization of the perforation and a more comfortable placement of the graft. We used the transcanal pathway predominantly. In reference to this approach, we observed that it appeared to be related with better clinical outcomes in a statistically significant manner ( $P=.003$ ). This might be attributable to the better prognosis of perforations in which this approach was used.

Regarding the status of the ear to be intervened, waiting at least 3 months since the last otorrhea seems a widely supported opinion.<sup>20,21</sup> In our centre, we follow these guidelines whenever possible. Sometimes this period of "inactivity" cannot be respected, as it would delay the surgery excessively. Moreover, some authors argue that there is no need to wait with a dry ear.<sup>15,26</sup> In our study, we found no statistically significant results relating the state of the pavilion or the presence of otorrhea at the time of the intervention with clinical outcome ( $P=.082$  and  $P=.643$ ). In contrast, we did find a higher mean hearing gain in patients who presented a non-pathological tympanic mucosa, with these differences being statistically significant ( $P=.049$ ).

With reference to the material used, we considered cases of cartilage plus perichondrium grafts as cartilage in the univariate analysis. This decision was based on the fact that such mixed grafts did not represent a large number and also that the use of cartilage with perichondrium does not change the anatomical outcome compared to cartilage alone to any great extent.<sup>27</sup>

In reviewing the medical literature, we must differentiate the impact of the material used on the anatomical outcome and on the functional outcome. In response to the first question, we noted that numerous authors support the cartilage graft as the material of choice due to its versatility, stability and excellent anatomical results.<sup>4,17,28-30</sup> Others, like Ben Gamra et al.<sup>24</sup> in their review article, found no statistically significant differences when comparing cartilage versus the fascia temporalis muscle at 2 years follow-up.

In our study, we found statistically significant differences in favour of perichondrium over other materials ( $P=.039$ ), a logical finding, since this material is predominantly used in smaller perforations.

As for functional outcome, no significant differences seem to exist when comparing cartilage with fascia or with perichondrium.<sup>2,4,24,28</sup> Moreover, Duckert et al.<sup>29</sup> showed excellent audiometric results with the use of cartilage, obtaining a postoperative DAT below 10dB in 87% of patients.

As was observed when relating the material used with clinical outcomes, we found a greater mean hearing gain with the perichondrium graft, with these differences being statistically significant ( $P=.013$ ).

Myringoplasty is conceptually limited to the closure of the perforation, without evaluating ossicular functionality. The state of the malleus, incus and stapes is an issue hardly referenced in the literature. In this respect, cartilage also has an important role, since it seems to maintain a good anatomical-audiometric relationship, regardless of the status of the ossicular chain.<sup>4,24,25</sup>

Aggarwal<sup>31</sup> believes that patients must be evaluated for a period of not less than 24 months, to assess the real capacity to maintain the tympanum sealed. Our limited follow-up of 6 months is based on the protocol followed in these patients. This deficit could be corrected by reassessing these patients at one year and at 2 years after the intervention.

Another, more common problem is the loss of patients during follow-up. These patients constitute a homogeneous group, in general those with better outcomes, who were discharged early.

There will always be variability in the results of an intervention, inherent to the characteristics of the patient, the ability of the surgeon and technical details.<sup>5</sup> The idea of standardizing parameters and unifying protocols based on scientific evidence is widely shared.

## Conclusion

In our experience and in that of other authors reviewed, myringoplasty is a suitable technique for restoring the integrity of the tympanum and obtaining a functional benefit.

The use of perichondrium and the transcanal approach favour anatomical success, being used in smaller defects, which are more easily definable. A dry pavilion and the posterior perforations seem to be related to a better functional prognosis.

## Conflict of Interest

The authors have no conflicts of interest to declare.

## Acknowledgments

We wish to thank all those who completed the data collection protocol. Without their collaboration, this study would not have been possible.

## References

- Heerman J. Auricular cartilage palisade tympano-, epitympano-, antrum- and mastoid-plasties. *Clin otolaryngol.* 1978;3:443-6.
- Bernal Sprekelsen M, Tomás Barberán M. Indicaciones, técnica y resultados anatómicos de la miringoplastia con cartilago en empalizada. *Acta Otorrinolaringol Esp.* 1997;48:279-86.
- Hammed M, Samir M, El Bigermy M. Fate of cartilage material used in middle ear surgery light and electron microscopy study. *Auris Nasus Larynx.* 1999;26:257-62.
- Donhoffer J. Cartilage tympanoplasty: indications, techniques, and outcomes in a 1000-patient series. *Laryngoscope.* 2003;113:1844-56.
- Labatut P, Sierra C, Mora E, Cobeta I. Miringoplastias primarias. Resultados a los 2 años de seguimiento. *Acta Otorrinolaringol Esp.* 2009;60:79-83.
- Committee on Hearing and Equilibrium. Guidelines for the evaluation of results of treatment of conductive hearing loss. American Academy of Otolaryngology-Head and Neck Surgery Foundation Inc. *Otolaryngol Head Neck Surg.* 1995;113:186-7.
- Altuna X, Navarro JJ, Martínez Z, Lobato R, Algaba J. Miringoplastia con cartilago "en isla". Resultados anatómicos y funcionales en 122 casos. *Acta Otorrinolaringol Esp.* 2010;61:100-5.
- Avilés Jurado FJ, Merán Gil JL, Tobed Secall M, Doménech Vadillo E, Masgoret Palau E, Martínez Novoa MD, et al. Miringoplastia: seguimiento auditivo y estudio de los factores pronósticos. *Acta Otorrinolaringol Esp.* 2009;60:169-75.
- Yuasa Y, Yuasa R. Post-operative results of simple underlay myringoplasty in better hearing hears. *Acta Otolaryngol.* 2008;128:139-43.
- Bhat NA, De R. Retrospective analysis of surgical outcome, symptom changes, and hearing improvement following myringoplasty. *J Otolaryngol.* 2000;29:229-32.
- Vartiainen E, Nuutinen J. Success and pitfalls in myringoplasty: follow-up study of 404 cases. *Am J Otol.* 1993;14:301-5.
- Amorós LI, Murcia V, Dalmau J, Carrasco M, López C, López R. Timpanoplastia con cartilago: 3 años de experiencia. *Acta Otorrinolaringol Esp.* 2002;53:578-82.
- Piédrola Maroto D, Escalona Gutiérrez JJ, Conde Jiménez M, Casado Morente JC, Povedano Rodríguez V, Benítez-Parejo N. Resultado funcional de las miringoplastias. *Acta Otorrinolaringol Esp.* 2010;61:94-9.
- Shrestha S, Sinha BK. Hearing results after myringoplasty. *Katmandú Univ Med J.* 2006;4:455-9.
- Frade González C, Castro Vilas C, Cabanas Rodríguez E, Elhendi W, Vaamonde Lago P, Labella Caballero T. Factores pronósticos del resultado anatómico y funcional de las miringoplastias. *Acta Otorrinolaringol Esp.* 2002;53:729-35.
- Gersdorff M, Garin P, Decat M, Juantegui M. Myringoplasty: long-term results in adults and children. *Am J Otol.* 1995;16:532-5.
- Adkins W, White B. Type I tympanoplasty: influencing factors. *Laryngoscope.* 1994;94:916-8.
- Applebaum EL, Deutsch EC. An endoscopic method of tympanic membrane fluorescein angiography. *Ann Otol Rhinol Laryngol.* 1986;95:439-43.
- Koch W, Friedman E, Mc Gill T, Healy G. Tympanoplasty in children. *Arch Otolaryngol Head Neck Surg.* 1990;116:35-40.
- Denoye F, Roger G, Chauvin P, Garabedian EN. Myringoplasty in children: predictive factors of outcome. *Laryngoscope.* 1999;109:47-51.
- Landa Aranzabal M, Rodríguez García L, Rivas Salas A. Miringoplastia: onlay versus underlay. Revisión de 460 casos. *Acta Otorrinolaringol Esp.* 1996;47:21-5.
- Boone RT, Gardner EK, Dornhoffer JL. Success of cartilage grafting in revision tympanoplasty without mastoidectomy. *Otol Neurotol.* 2004;25:678-81.
- Chandrasekhar SS, House JW, Degan LJ. Pediatric tympanoplasty: a 10-year experience. *Arch Otolaryngol Head Neck Surg.* 1995;121:873-8.

24. Ben Gamra O, Mbarek C, Khammassi K. Cartilage graft in type I tympanoplasty: audiological and ontological outcome. *Eur Arch Otorhinolaryngol.* 2008;265:739–42.
25. Abou Mayaleh H, Heshiki R, Portmann D, Négrevèrgne M. Reinforcing tympanoplasty with cartilage mosaic (differences from the palisade technique). *Rev Laryngol Otol Rhinol.* 2005;126:181–9.
26. Albera R, Ferrero V, Lacilla M, Canale A. Tympanic reperforation in myringoplasty: evaluation of prognostic factors. *Ann Otol Rhinol Laryngol.* 2006;115:875–9.
27. Baumann I, Diedrichs HW, Plinkert PK, Zenner HP. Autologous tissue in initial type I and type III tympanoplasty operations in chronic suppurative otitis media. *HNO.* 1997;45:990–6.
28. Gerber MJ, Mason JC, Lambert PR. Hearing results after primary cartilage tympanoplasty. *Laryngoscope.* 2000;110:1994–9.
29. Duckert LG, Müller J, Makielski KH, Helms J. Composite autograft “shield” reconstruction of remanant tympanic membranes. *Am J Otol.* 1995;16:21–6.
30. Milewski C. Composite graft tympanoplasty in the treatment of ears with advanced middle ear pathology. *Laryngoscope.* 1993;103:1352–6.
31. Aggarwal R. Myringoplasty. *J Laryngol Otol.* 2006;120:429–32.