


apunts

MEDICINA DE L'ESPORT

www.apunts.org



CLINICAL CASE

Injury to the rectus abdominis muscle of a volleyball player

Antonio Turmo Garuz^{a,*}, Luís Til Pérez^a, Montse Bellver Vives^a and Evangelos Papousidakis^b

^aCAR de Sant Cugat - Consorci Sanitari de Terrassa, Barcelona, Spain

^bEscola de Medicina de l'Esport, Universitat de Barcelona, Barcelona, Spain

Received January 11, 2010; accepted February 2, 2010

KEYWORDS

Rectus abdominis;
Muscle injury;
Beach volley

Abstract

A case of ruptured rectus abdominis muscle in a professional volleyball player is presented and discussed. The injury was located near the deep fascia of the upper stomach muscle on the non-dominant side. This injury is rarely specifically mentioned in the literature and there are few reported cases. The injury mechanism is usually indirect at the time of the flexion/extension transition when serving or attacking in the case of volleyball. The player remains active despite the injury and for this reason the treatment had to be modified.

© 2010 Consell Català de l'Esport. Generalitat de Catalunya. Published by Elsevier España, S.L. All rights reserved.

PALABRAS CLAVE

Recto abdominal;
Lesión muscular;
Voleibol playa

Lesión muscular de recto abdominal en un jugador de voleibol

Resumen

Se presenta y se discute un caso de rotura de músculo recto abdominal en un jugador profesional de voleibol playa. La lesión se localiza próxima a la aponeurosis profunda del vientre muscular superior en el lado no dominante. En la literatura epidemiológica pocas veces se contempla, de manera específica, esta lesión, y existen pocos casos descritos. El mecanismo de lesión suele ser indirecto en el momento de la transición extensión-flexión durante el gesto de saque o ataque en el caso del voleibol. En nuestro caso la ecografía es la herramienta de confirmación diagnóstica. A pesar de la lesión, el jugador se mantuvo activo, por lo cual debió modificarse la pauta de tratamiento.

© 2010 Consell Català de l'Esport. Generalitat de Catalunya. Publicado por Elsevier España, S.L. Todos los derechos reservados

*Author for correspondence.

E-mail address: turmo@car.edu (A. Turmo).

Introduction

The rectus abdominis muscle (RA) originates from the anterior surface of the symphysis pubis and the crest of the superior pubic ramus and is inserted in the 5th, 6th and 7th rib cartilages. It contains three fibrous bands that start from the anterior aponeurosis and cross the muscle mass^{1,2}.

The abdominal muscles are particularly active during sports activities³. The torsion movements in the serve or attack in volleyball involve sequences comparable to that of the serve in tennis or batting in baseball: they start in the legs, transferring to the trunk, the shoulder and the arm^{4,5}.

Injury to the RA muscle is produced during brusque flexo-extension movements and rotation of the trunk during eccentric contraction⁶ or concentric eccentric transition in the serve, or the attack. Sports that involve hitting a ball using the upper limbs can lead to injuries to the RA muscle. There is less information available about these injuries than is commonly thought⁷. However, some studies explicitly consider such injuries⁸⁻¹⁰.

Presentation of the case study

This case study concerns a 28 year old, right handed, beach volleyball player, of international olympic standard,

who was treated by the medical services at the Sant Cugat High Performance Centre for pain in the anterior left upper quadrant of the anterior abdominal wall after performing an attack movement when playing in a competition. This movement consisted of the hyper-extension of the lumbar column, stretching of the abdominal musculature during eccentric contraction followed by a concentric phase that led to a flexing and rotation of the trunk towards the injured side during the attack movement.

The injuries did not cause the player to stop playing. This continued activity led to several episodes of sharp pain and made suitable treatment difficult. The examination, carried out a week after the episode, showed selective pain of the left upper RA muscle around the umbilical area. Resisted flexion and muscle stretching were painful.

Despite 7 days having lapsed since the injury, a disruption of the normal fibrillar pattern was observed, with hemorrhagic suffusion across the whole of the wound, and perilesional oedema (Figures 1 and 2). Ultrasound examination also showed a fibrous image that, after questioning the patient, was concluded to be an old lesion in the same location in the abdomen and asymptomatic at the time of the examination (Figure 3).

Once a diagnosis had been made it was decided to plan treatment as if the injury were acute:

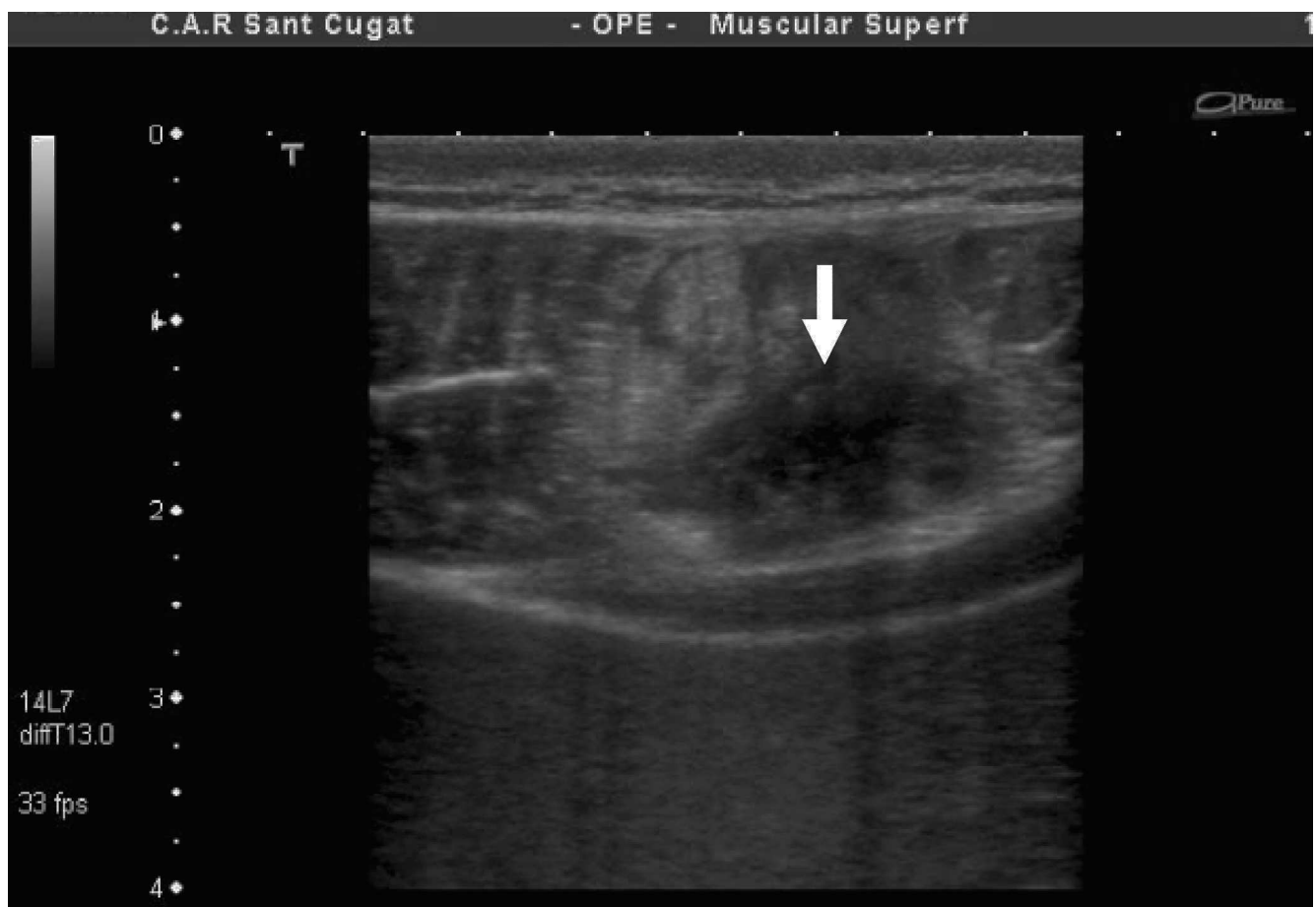

Figure 1 Transverse ultrasound image of the injury located in the area close to deep fascia of the right of the image.

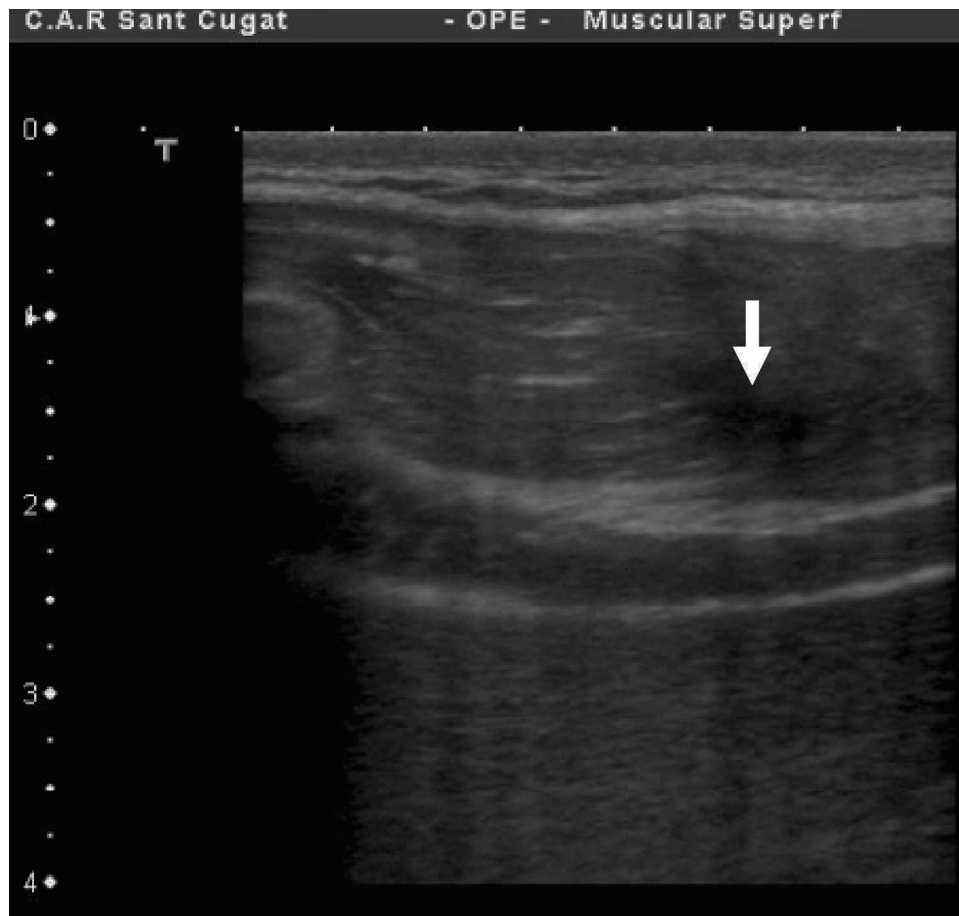


Figure 2 Longitudinal ultrasound image of the same injury.

- Three days rest with the application of local cold therapy.
- Specific physiotherapy techniques.
- Progressive rehabilitation:
 - Body building.
 - Progressive exercises of receiving and hitting a ball.
 - Stretches, isometric exercises and finally eccentric exercises as tolerated.

The persistence of pain made it necessary to use corticosteroid infiltrations to solve the problem.

Discussion

Injury of the RA muscle is characteristic of throwing, hitting and batting activities. It is surprising that despite being activities that are classically related to tennis and volleyball this type of injury is poorly represented in the literature. Johnson⁷ argues that injuries to the muscles of the abdominal wall are thought to be common although epidemiological studies do not corroborate this theory. This is particularly so for volleyball, where injury to the abdominal muscles is not recorded in the majority of cases¹¹⁻¹⁴. Nor is any such

injury included in the description of injuries to the trunk and abdomen such as those described in Kujala et al¹⁵. They found that in a population of more than 85,000 volleyball players these injuries represented 0.09% of the total, giving a rate of 1:1000 players per year of exposure. This low rate can clearly be seen in the epidemiological records. Data from the National Collegiate Athletic Association (NCAA) shows that football and wrestling are the sports that exhibit the highest incidence of injury to the abdominal wall. In volleyball the injury rate is 0.48:1000 players per year⁷. There is only one published case of professional beach volleyball where this injury was recorded as needing medical attention but did not result in a loss of time spent training¹⁶.

Both epidemiological and clinical articles have been published about this injury in relation to tennis^{2,17-19}. Eccentric stretching followed by concentric contraction of the non-dominant RA muscle during the impact phase of the serve is the accepted mechanism of the injury²⁰. The tear generally occurs in the RA muscle contralateral to the hitting arm at the periumbilical level^{2,19}.

Our case was similar to those described by Maquirriain^{3,19} and Connell² in that the tear occurred contralaterally to the attack arm, in the upper abdomen, near the deep aponeurosis of the muscle.

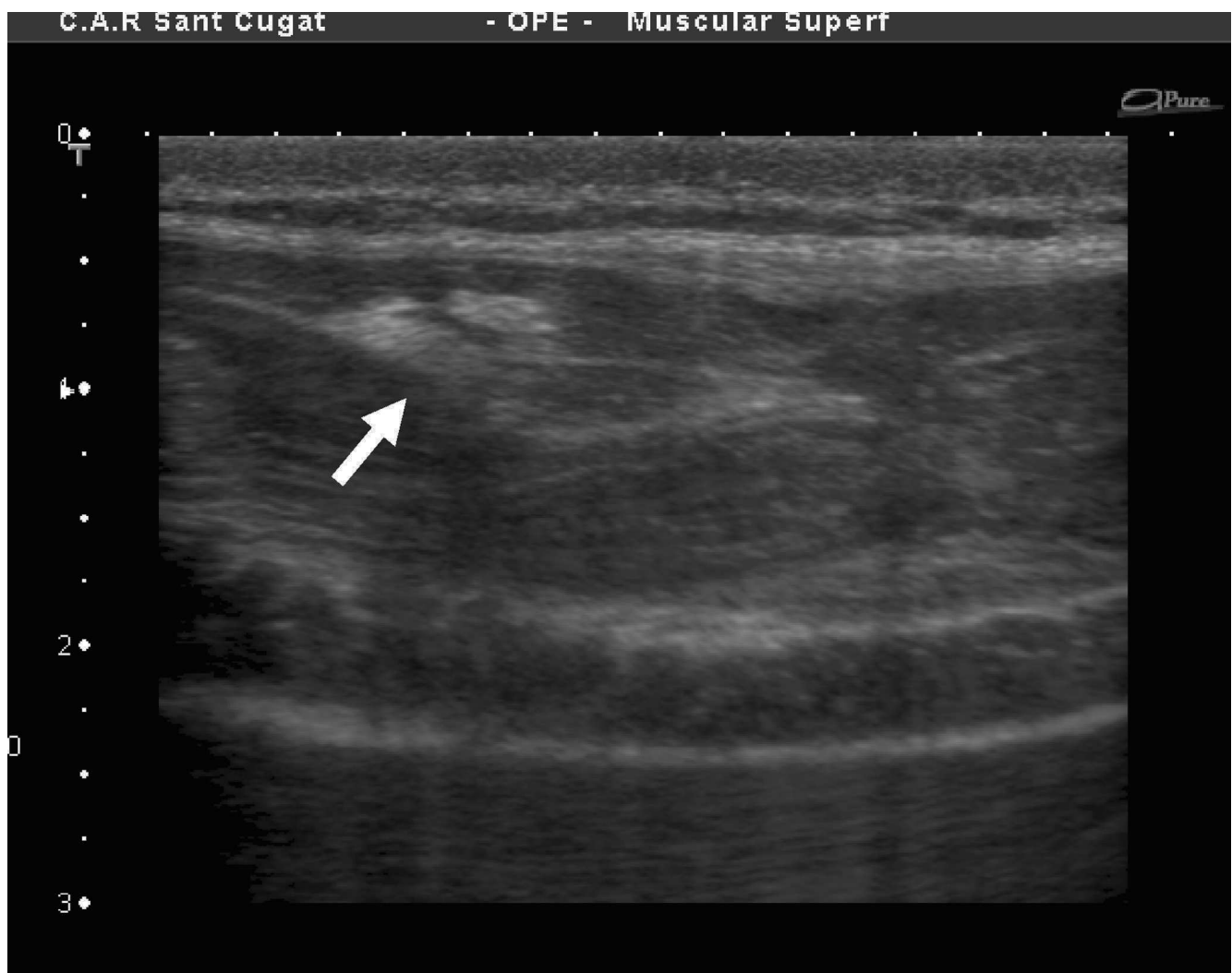

Figure 3 Fibrous scar from an old injury to the rectus abdominis muscle in the same player.

In tennis players an asymmetry occurs between each side of the RA muscle². Significant differences have been reported between the measurements of the anteroposterior diameter of the dominant side ($21.2 \text{ mm} \pm 1.93$) compared with the non-dominant (28.2 ± 1.93). The same phenomenon can be seen in volleyball attackers. Figure 4 relates to a health player belonging to the national team where the same situation occurs.

When hitting the ball, there is an asymmetric increase in EMG activity in the RA muscle on the non-dominant side⁵. This is at its greatest when the arm speed is increasing prior to the hit and to the hip on the same side being flexed²⁰, which is the cause of the hypertrophy. The RA muscle is considered to be a muscle with dynamic rather than static function²¹ and one that has a greater tendency to shorten. It is probably for these reasons that it is more susceptible to injury.

Other sports where incidence of this type of injury can be seen are in handball^{8, 22, 23} and from our own personal experience women's artistic gymnastics.

Suitable treatment^{24, 25} can bring about a rapid recovery

(3 weeks). However experience shows that this type of injury is one that has a tendency to become chronic because it does not cause the sufferer to stop playing completely and because of the lack of importance that trainers and players give to the problem. Although muscle demand in volleyball is constant, specific movements can be changed using various techniques but maintaining this level of activity will worsen the injury process.

Summary

- Injury to the rectus abdominis occurs more frequently than shown in the literature.
- Suitable treatment can resolve the problem within a short period of time.
- The condition tends to become chronic due to the lack of importance it is given.
- Corticosteroid infiltrations provide an alternative treatment in chronic situations.

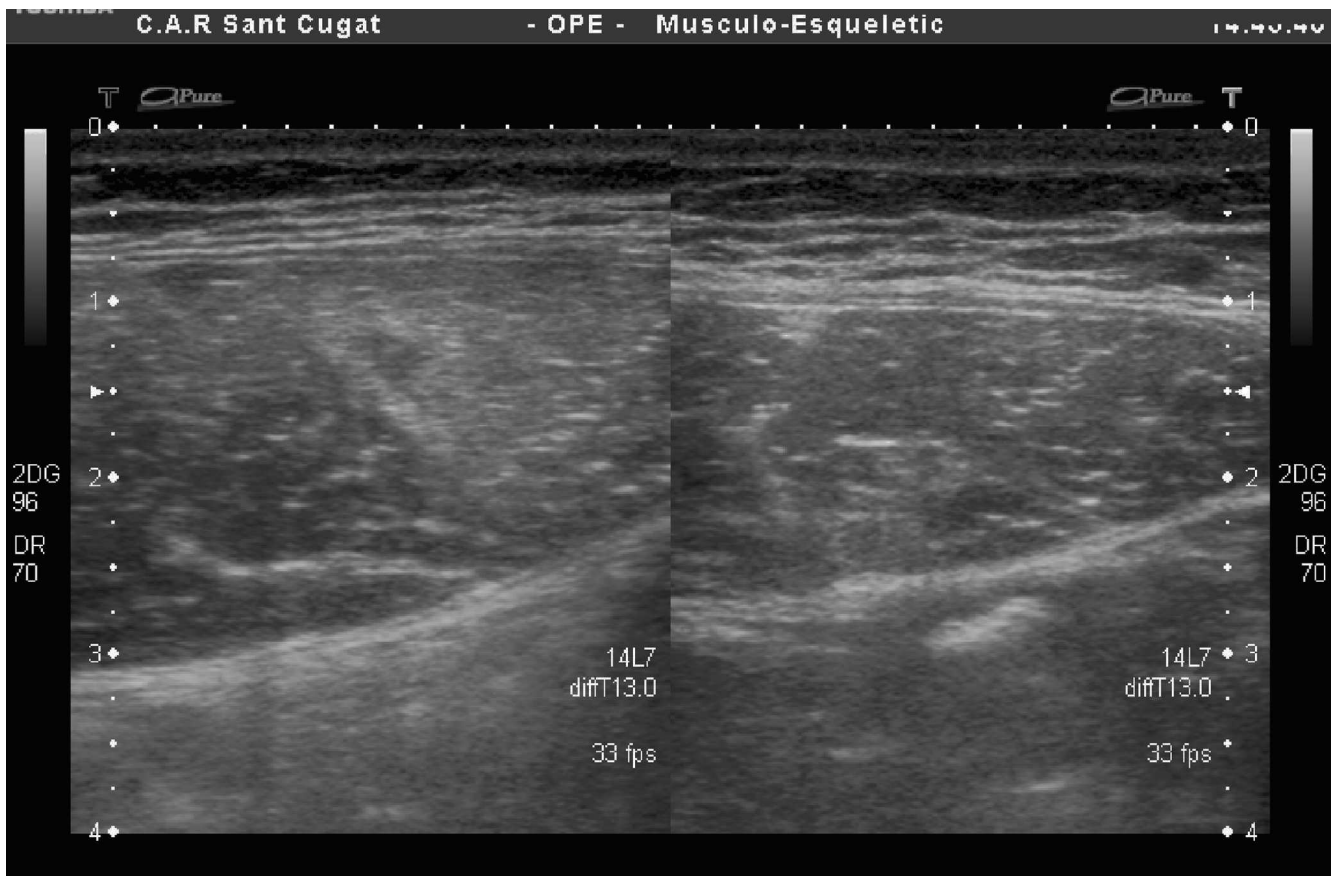


Figure 4 Rectus abdominis asymmetry muscle in a healthy professional player: 25 mm in the non-dominant left side, 20 mm in the right.

Bibliografia

- Sinnatamby CS, editor. *Lat's anatomy*, 10th ed. Edinburgh, Scotland: Churchill Livingstone, 1999. p. 218.
- Connell D, Ali K, Javid M, Bell P, Batt M, Kemp S. Sonography and MRI of rectus abdominis muscle strain in elite tennis players. *AJR*. 2006;187:1457-61.
- Maquirriain J. Uncommon abdominal muscle injury in a tennis player: internal oblique strain. *Br J Sports Med*. 2006;40:462-3.
- Shaffer B, Jobe FW, Pink M, Perry J. Baseball batting. An electromyographic study. *Clin Orthop*. 1993;292:285-93.
- Chow JW, Shim JS, Lim YT. Lower trunk muscle activity during the tennis serve. *J Science Med Sports*. 2003;4:512-8.
- Garrett WE Jr. Muscle strain injuries. *Am J Sports Med*. 1996;24 (Suppl 6):2-8.
- Johnson R. Abdominal wall injuries: Rectus abdominis strains, oblique strains, rectus sheath hematoma. *Current Sports Medicine Reports*. 2006;5:99-103.
- Seil R, Rupp S, Tempelhof S, Kohn D. Sports injuries in team handball. A one-year prospective study of sixteen men's senior teams of a superior nonprofessional level. *Am J Sports Med*. 1998;26:681-7.
- Emery C, Meeuwisse W, Powel J. Groin and abdominal strain injuries in the national hockey league. *Clin J Sports Med*. 1999;9:151-6.
- Orchard J, Seward H. Epidemiology of injuries in the Australian Football League, seasons 1997-2000. *Br J Sports Med*. 2002;36:39-45.
- Aagaard H, Jorgensen U. Injuries in elite volleyball. *Scand J Med Sports*. 1996;6:228-32.
- Bahr R, Bahr A. Incidence of acute volleyball injuries: a prospective cohort study of injury mechanisms and risk factors. *Scand J Med Sci Sports*. 1997;7:166-71.
- Zetou E, Malliou P, Lola A, Tsiganos G, Godolias G. Factors related to the incidence of injuries appearance to volleyball players. *Journal of Back and Musculoskeletal Rehabilitation*. 2006;19:129-34.
- Augustsson S, Augustsson J, Thomee R, Svantesson U. Injuries and preventive actions in elite Swedish volleyball. *Scand J Med Sci Sports*. 2006;16:433-40.
- Kujala U, Taimels S, Antd-Poh I, Orava S, Tuominen R, Myllynen P. Acute injuries in soccer, ice hockey, volleyball, basketball, judo, and karate: analysis of national registry data. *BMJ*. 1995;311:1465-8.
- Bahr R, Reeser JC. Injuries among world-class professional beach volleyball players. *Am J Sports Med*. 2003;31:119-25.
- Balduini FC. Abdominal and groin injuries in tennis. *Clin Sports Med*. 1988;7:5-9.
- Lehman RC. Thoracoabdominal musculoskeletal injuries in racket sports. *Clin Sports Med*. 1988;7:267-76.
- Maquirriain J, Ghisi JP, Kokalj AM. Rectus abdominis muscle strains in tennis players. *Br. J. Sports Med*. 2007;41:842-8.
- Konrad P, Schmitz K, Denner A. Neuromuscular evaluation of trunk-training exercises. *Journal of Athletic Training*. 2001;36:109-18.

21. Norris CM. Functional load abdominal training: part 1. *Phys Ther Sports*. 2001;2:29-39.
22. Langevoort G, Myklebust G, Dvorak J, Junge A. Handball injuries during major international tournaments. *Scand J Med Sci Sports*. 2007;17:400-7.
23. Kolt GS, Kirkby RJ. Epidemiology of injury in elite and subelite female gymnasts: a comparison of retrospective and prospective findings. *Br J Sports Med*. 1999;33:312-8.
24. Arnason A. ¿Cuál es la evidencia científica de los programas de prevención de la lesión muscular? *Apunts Med Esport*. 2009; 164:174-8.
25. Guía de práctica clínica de las lesiones musculares. Epidemiología, diagnóstico, tratamiento y prevención Versión 4.5 (9 de febrero de 2009). *Apunts Med Esport*. 2009. 164:179-203.